



# MACRO-LOCK<sup>®</sup> Oval<sup>™</sup>

Round-Flared-Oval Fiber Post



## Step By Step Clinical Technique

- Canine incisor with a failed composite restoration.
- Restored with Macro-Lock Oval #3
- Cemented with Sealbond Ultima and Corecem

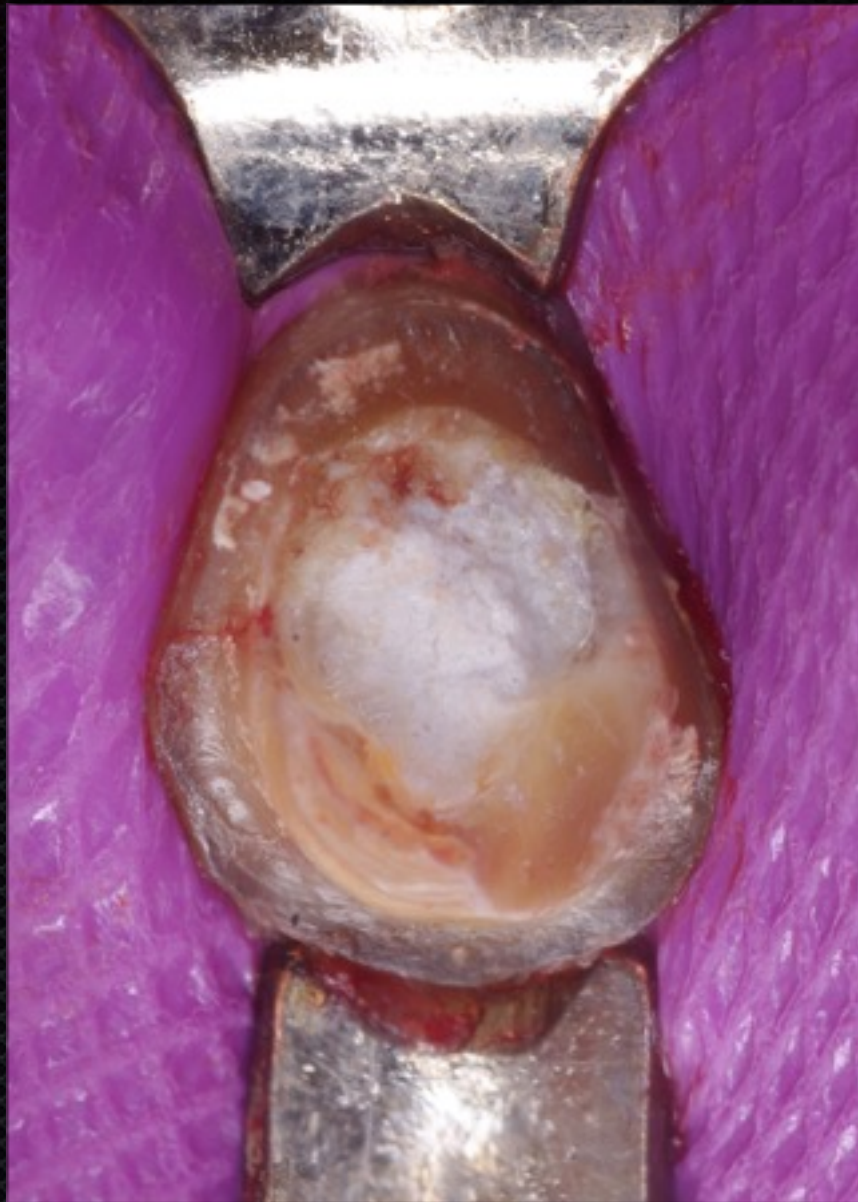Courtesy of  
Prof. Dr. Alejandro Bertoldi Hepburn  
Universidad del Desarrollo  
(UDD)  
Concepcion, Chile



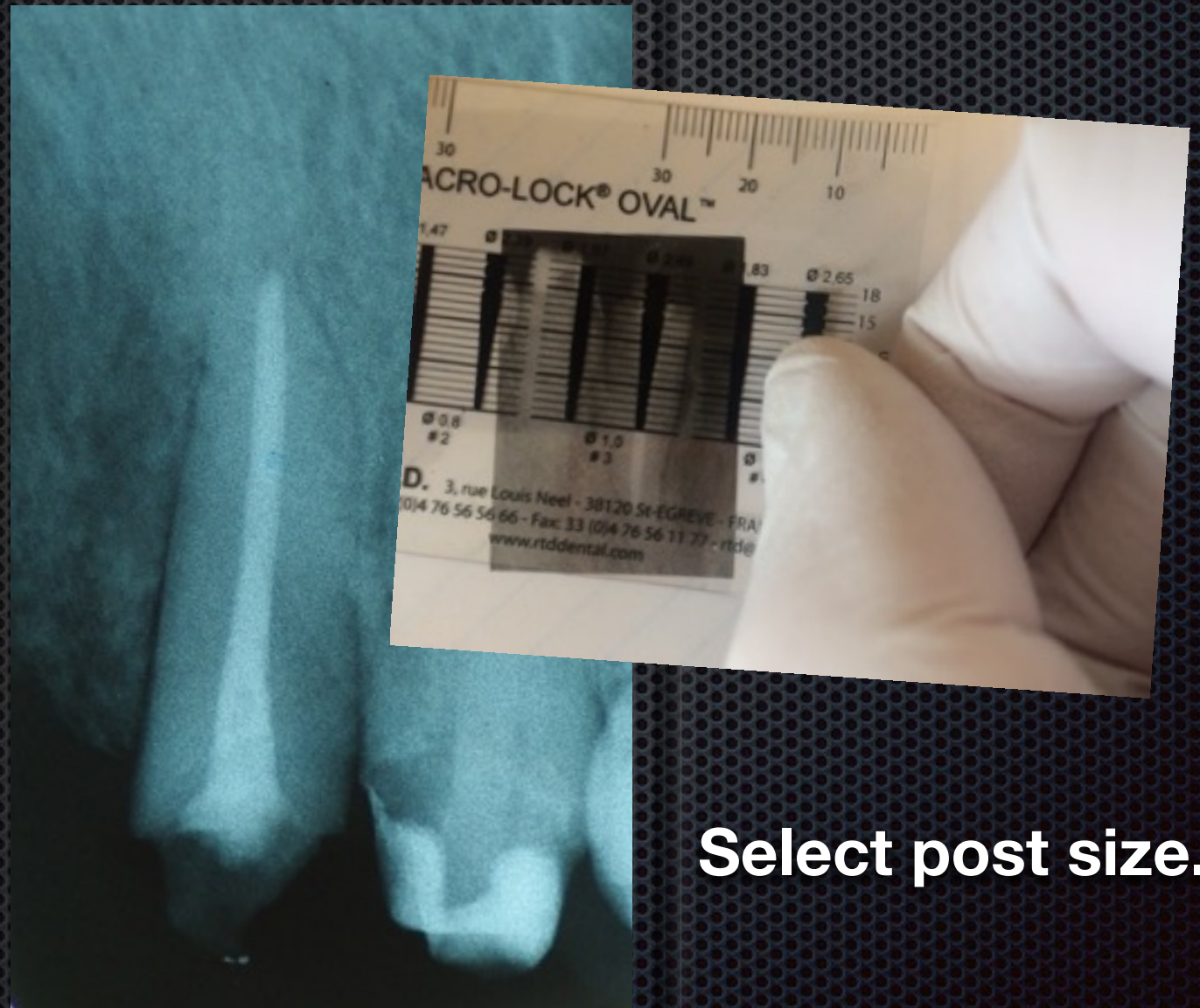*"Our fiber expertise is your strength"*



# Clinical Technique



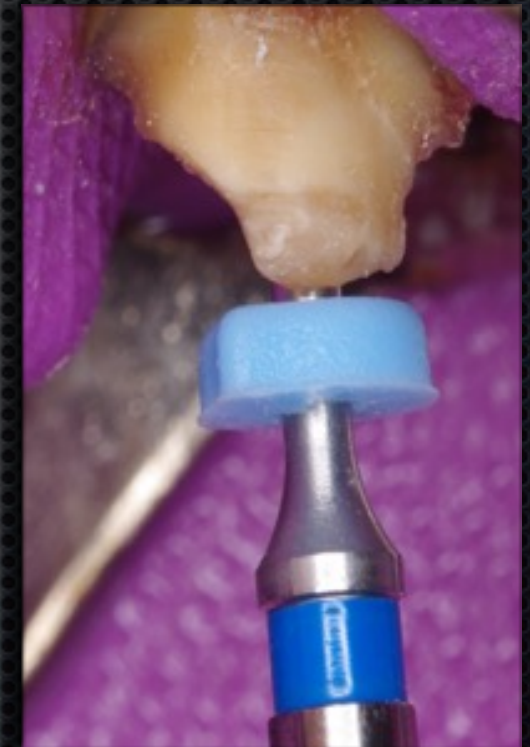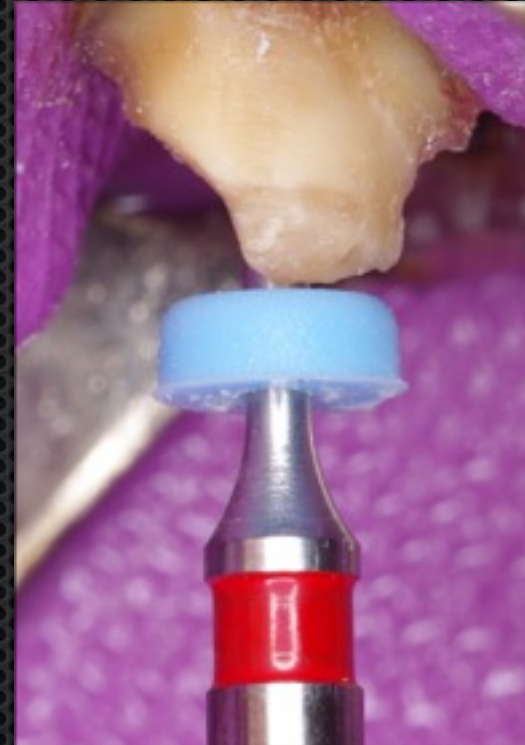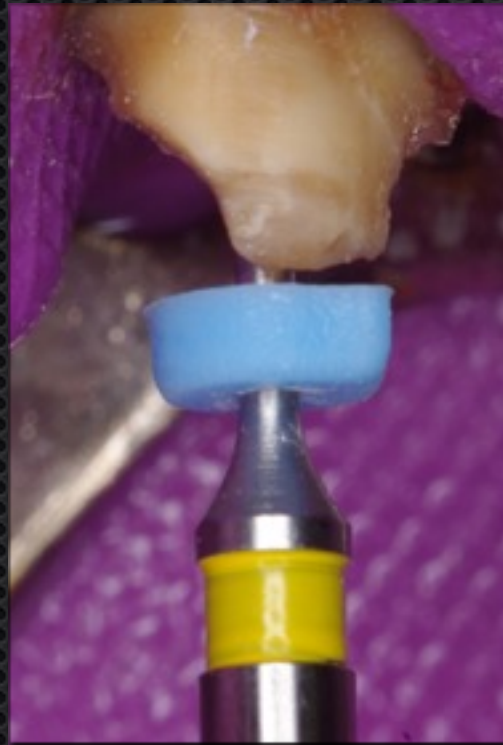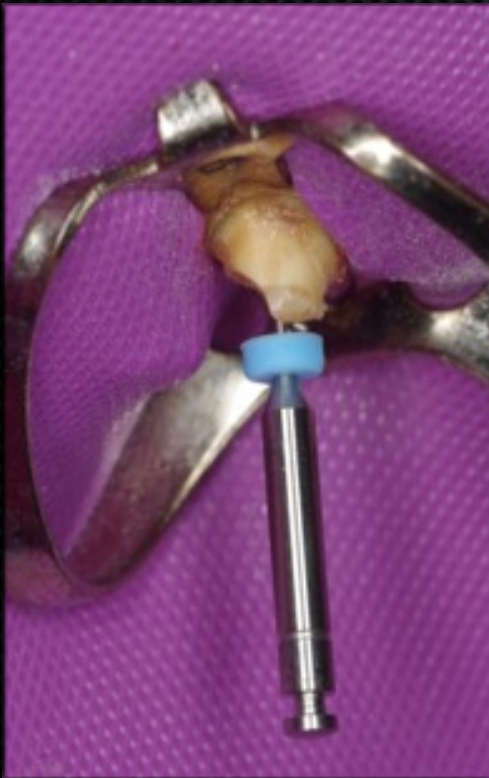**Remove old restoration.**



**Select post size.**



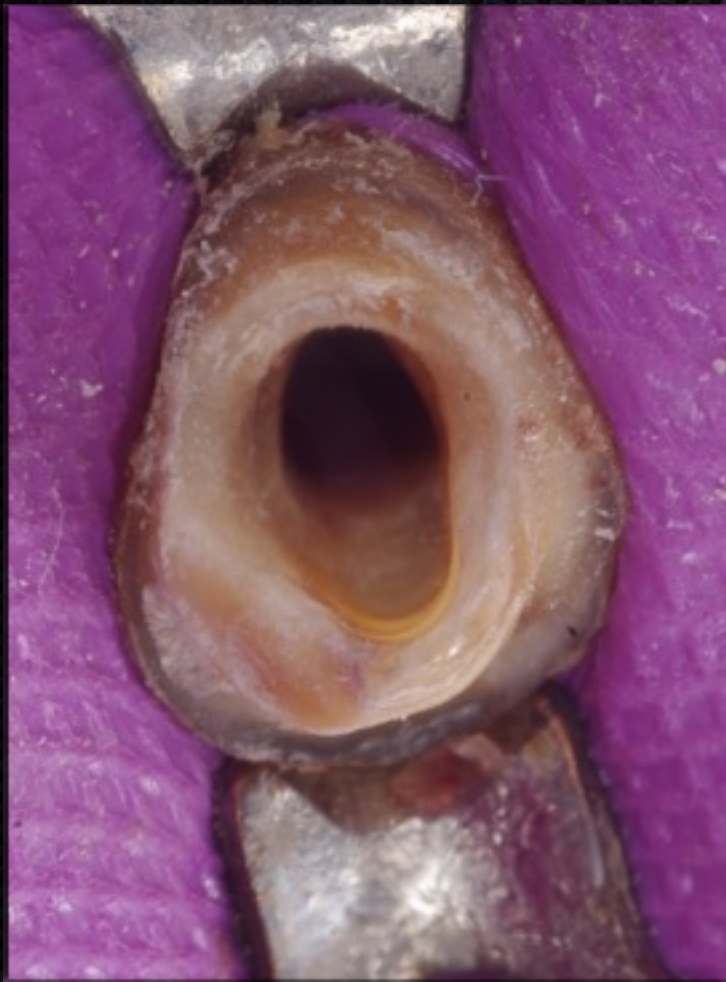# Clinical Technique



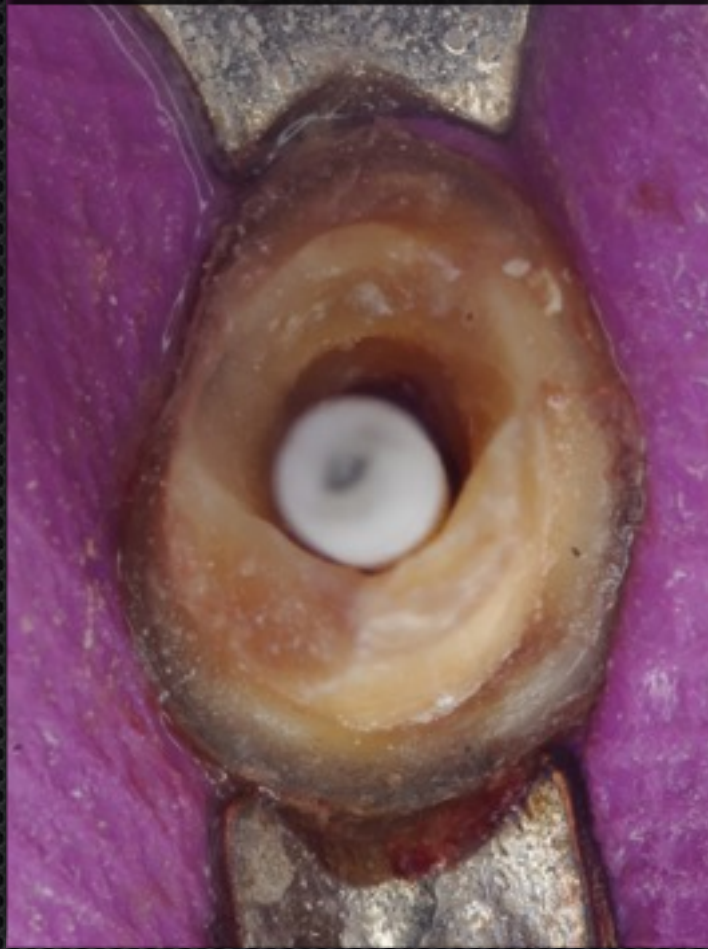**Prepare post space: Starter Drill and then sequential Finishing Drills**



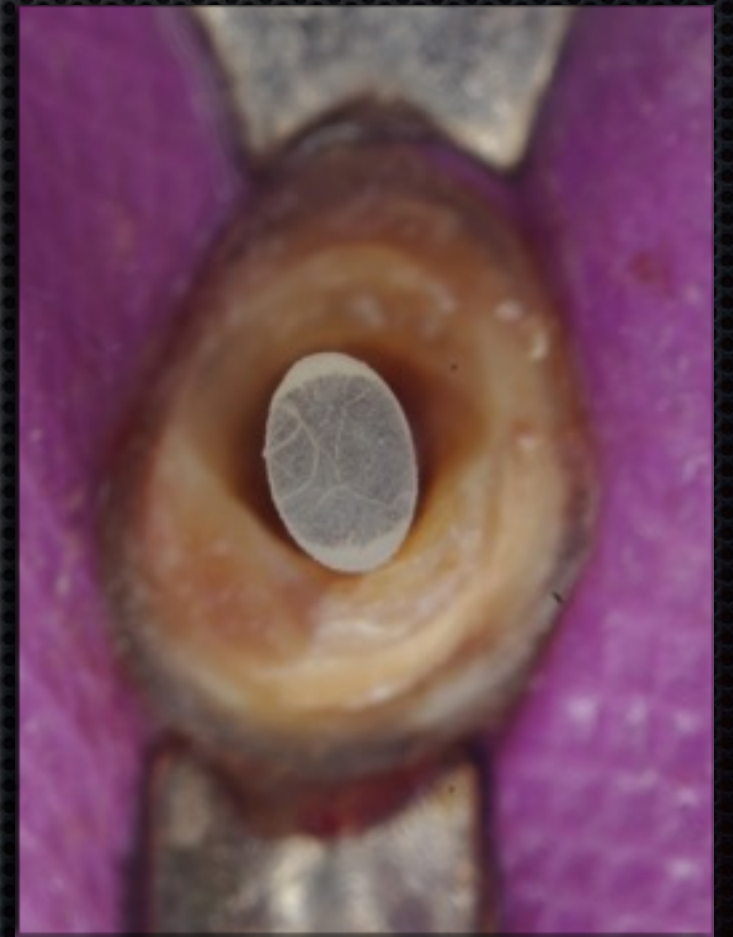# Clinical Technique



**Prepared post space**




**Round post does  
NOT FIT**




**Try - in Oval Post**



# Clinical Technique



**Apply bonding agent  
to post**



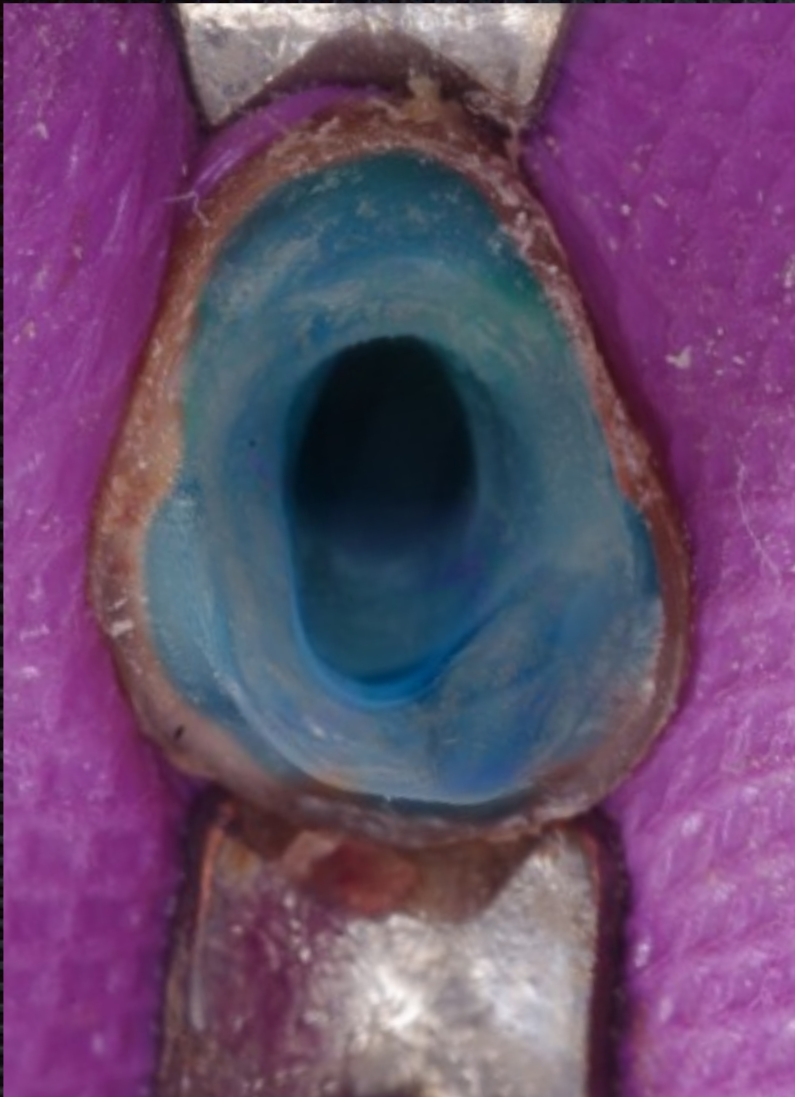**Air-dry bonding agent**

**Light-cure bonding agent**



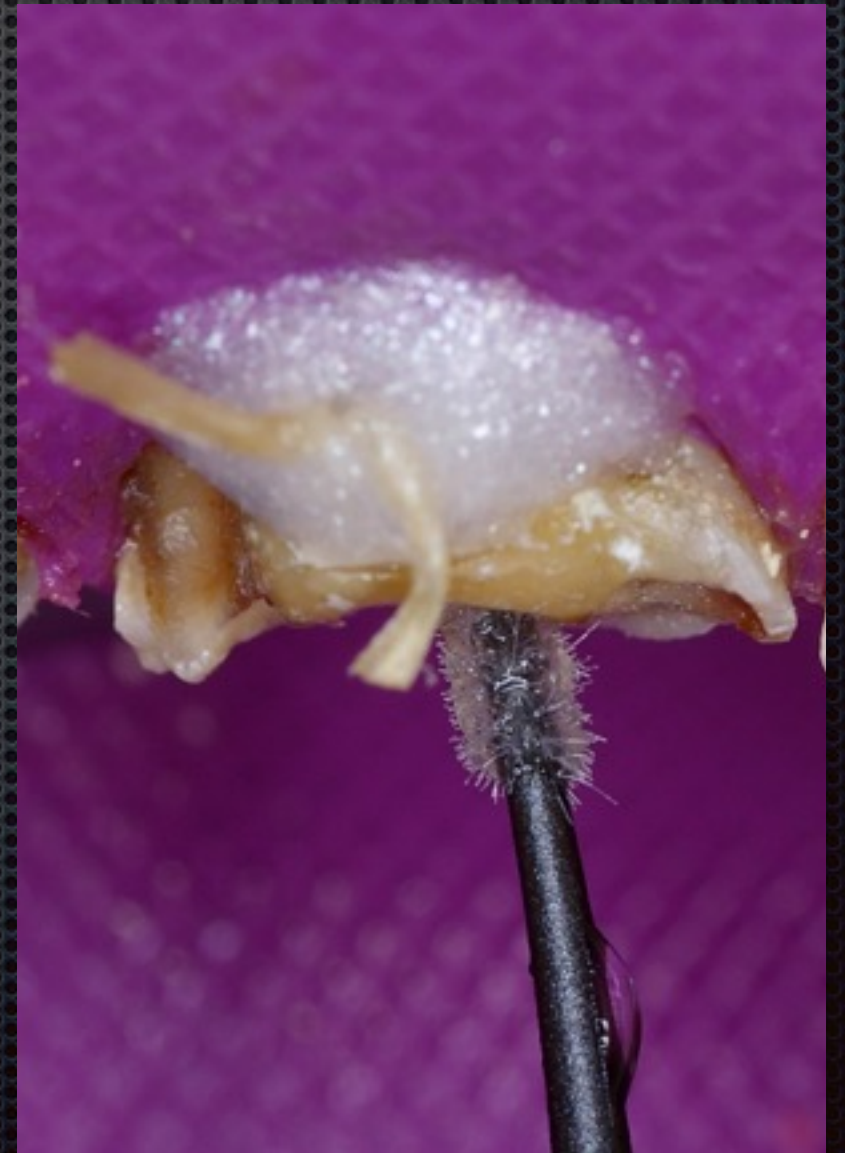

# Clinical Technique



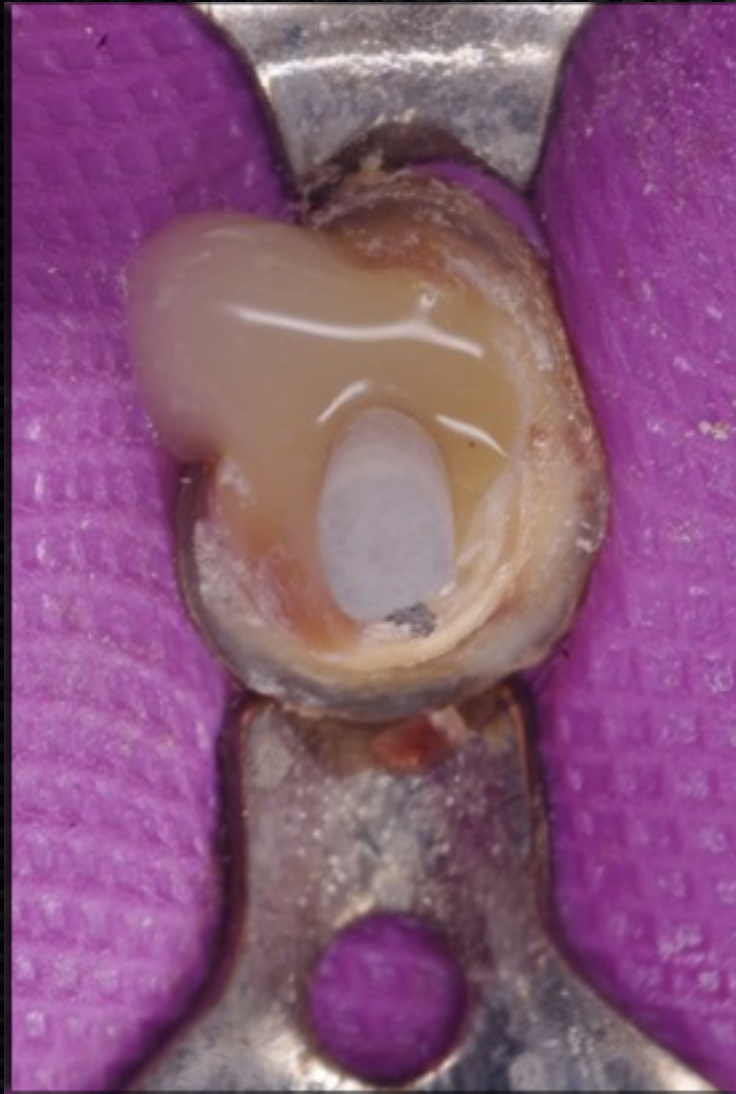**Acid-etch the space and tooth structure  
Rinse away etchant, Remove excess water**

**Apply bonding agent/adhesive  
Light-cure all adhesive**

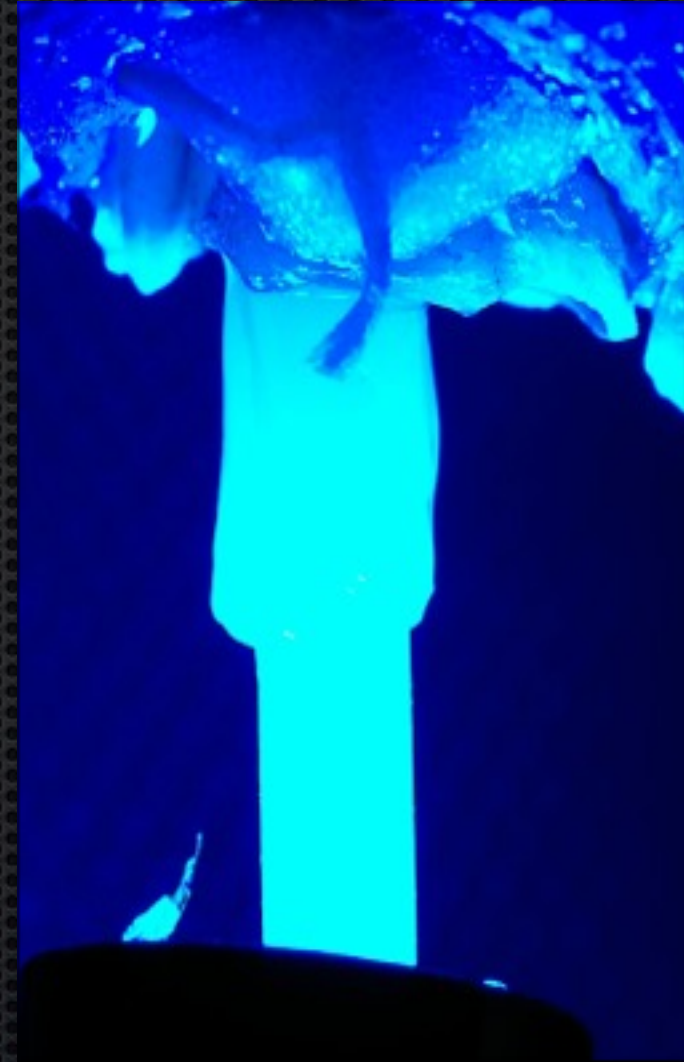



# Clinical Technique



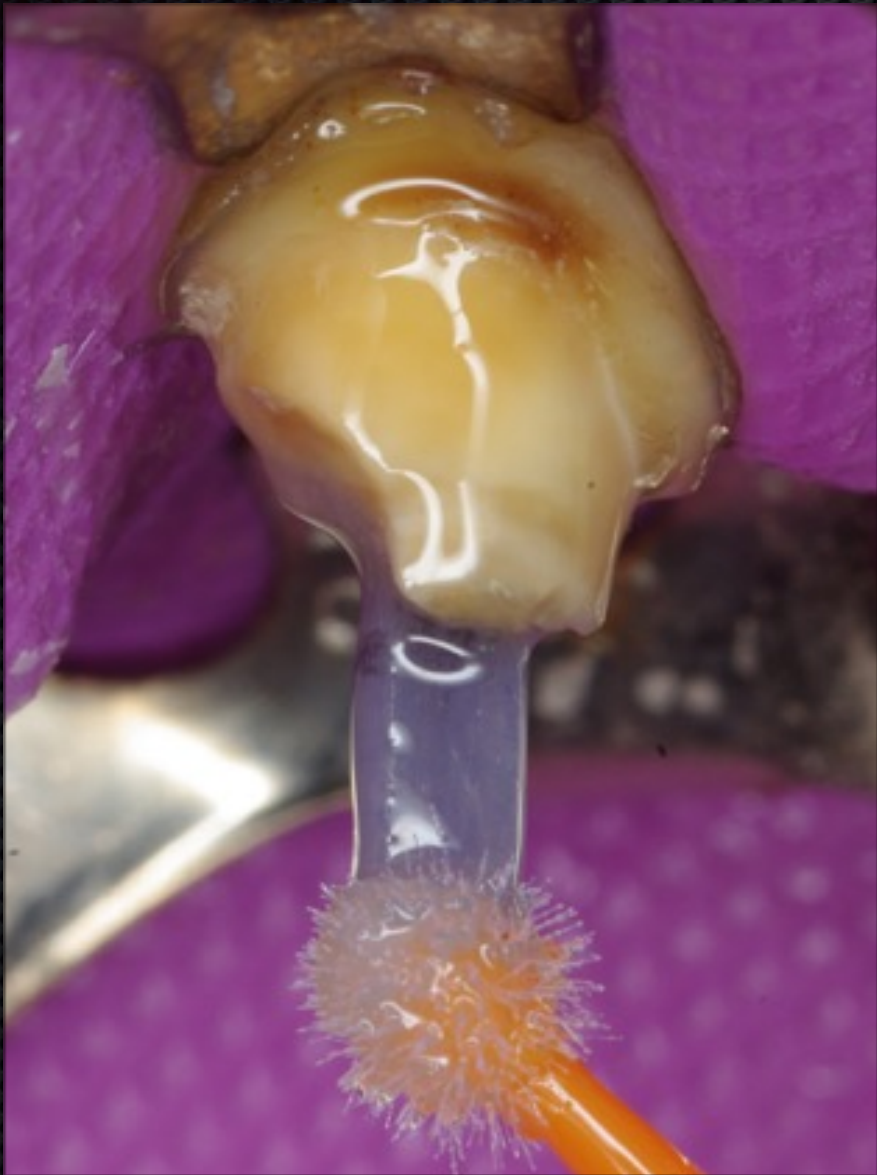**Place cement and then post**



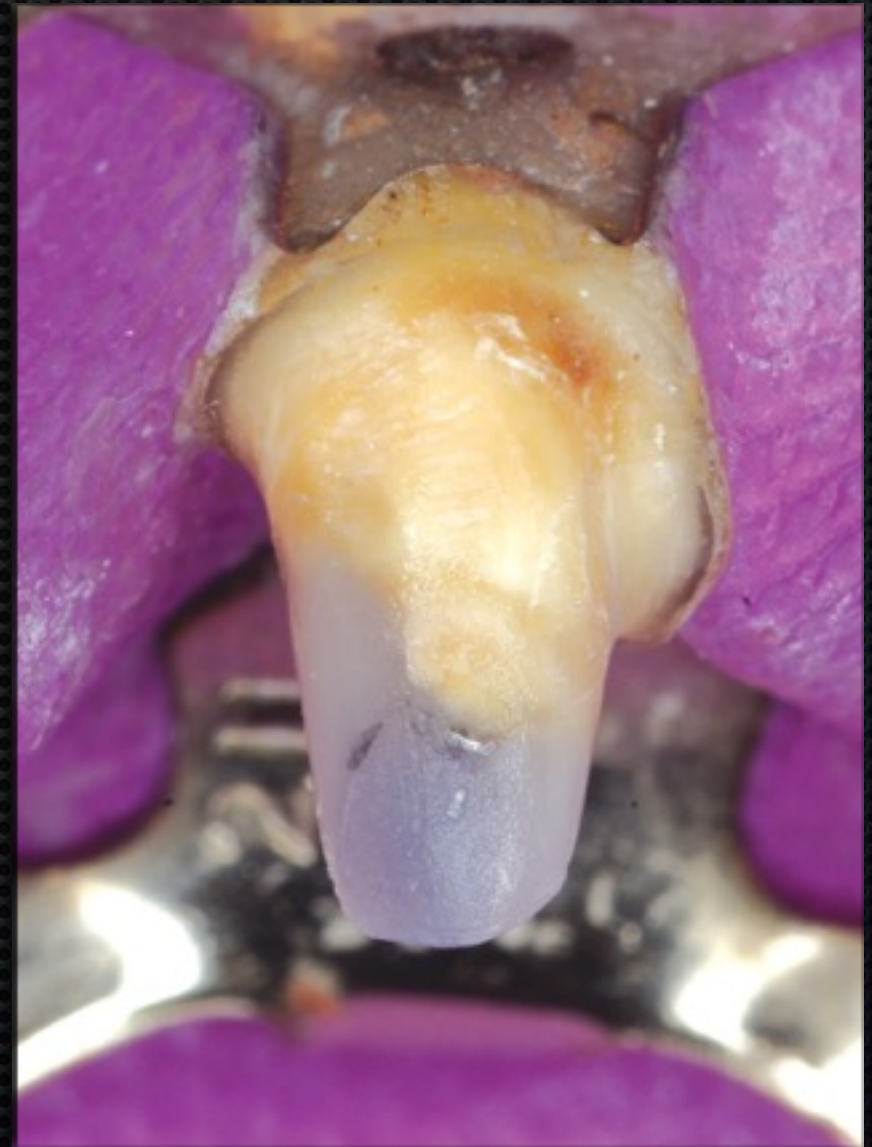**Light-cure the cement**



# Clinical Technique



**Apply bonding agent/adhesive**

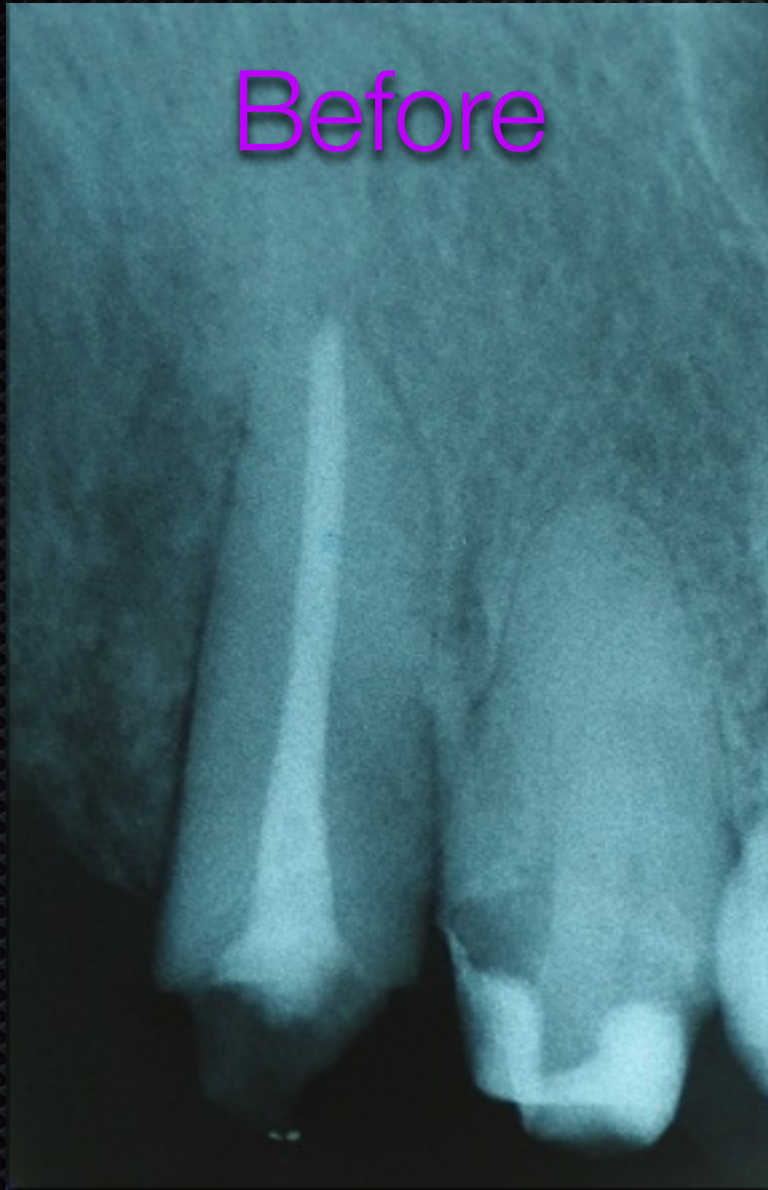

**Place & cure core composite**



# Final Radiograph

Before



After

